



Topical oral 1-tetradecanol complex in the treatment of periodontal diseases in cats

Fernanda Maria Lopes Kubitza¹ 
and James Mudie George Anthony²

Journal of Feline Medicine and Surgery

2019, Vol. 21(12) 1141–1148

© The Author(s) 2019

Article reuse guidelines:

sagepub.com/journals-permissions

DOI: 10.1177/1098612X18820734

journals.sagepub.com/home/jfm

This paper was handled and processed by the American Editorial Office (AAFP) for publication in *JFMS*



Abstract

Objectives The aim of this study was to evaluate the outcomes of the treatment of chronic periodontal disease with an oral application of tetradecanol complex (1-TDC) in cats.

Methods The test group (n = 9) received 1-TDC (525 mg per gel capsule/day) and the placebo group (n = 4) received olive oil (0.25 ml per gel capsule/day) for 6 weeks.

Results Oral treatment with 1-TDC resulted in significant reductions in all parameters of clinical periodontal disease except tooth mobility at 6 weeks. The 1-TDC group exhibited a statistically significant reduction in pocket depth, clinical attachment loss, gingival index and bleeding on probing after treatment at 6 weeks, whereas the placebo group did not show any significant change.

Conclusions and relevance Chronic inflammation associated with periodontal diseases leads to periodontal tissue destruction. As a result, modulation of the host response has been included in the treatment protocol for periodontal diseases. Fatty acids present anti-inflammatory properties and are being investigated for use in the treatment and prevention of progressive periodontal diseases.

Keywords: Gingivitis; periodontitis; fatty acids; immunomodulators; MUFAs

Accepted: 26 November 2018

Introduction

Periodontal diseases are the most common oral diseases in cats and dogs of all ages, though it is more prevalent in older animals.^{1–4} They refer to a group of inflammatory diseases that cause extensive destruction to periodontal tissues. Plaque-induced gingivitis and chronic periodontitis are the most prevalent types. Dental plaque bacteria are the major agents responsible for them, mainly those considered periodontopathogens, but the host plays an equally important role in evoking immune responses.^{4–10}

Gingivitis is clinically characterized by redness, swelling, bleeding and pain. If left untreated, periodontal diseases often progress into more severe forms and results in loss of supporting tissues, including periodontal ligament and alveolar bone.^{2,11} Increased depth of the periodontal pocket, gingival recession, increased mobility of the tooth, furcation exposure and, eventually, tooth exfoliation are related to more severe presentations of periodontal diseases.^{5,12,13}

Despite gingivitis preceding the onset of periodontitis, not all gingivitis develops into periodontitis. This means that host susceptibility is essential for the establishment of periodontitis, and although plaque accumulation is necessary, it is not sufficient by itself for the development of periodontitis.⁵

Tooth resorption, the second most common dental condition in cats, has been found to be associated with inflammatory conditions such as periodontal diseases.^{14–16} It is also believed that bacterial and viral antigens are involved in feline chronic gingivostomatitis,

¹Campos de Santo Antonio, Itu, São Paulo, Brazil

²Red Bank Veterinary Hospital, Dentistry and Oral Surgery, Red Bank, NJ, USA

Corresponding author:

Fernanda Maria Lopes Kubitza DVM, MSc, Rua Manoel Bandeira 135, Campos de Santo Antonio, Itu, São Paulo 13305-412, Brazil
Email: lopesfm@usp.br

associated with either an inadequate or exaggerated host response.^{4,17}

Severe periodontal diseases can result in the release of bacteria, cellular degradation by-products and inflammatory mediators into the bloodstream, which can accelerate a systemic inflammatory response and increase the risk of disease in distant organs such as the heart, kidneys and joints, and systemic conditions such as diabetes mellitus, osteoporosis, rheumatoid arthritis and adverse effects on pregnancy in humans.^{3,18–21}

Fatty acids in the treatment of inflammatory diseases

Fatty acids are increasingly being recognized as a central feature of many biological processes.²² They are essential components of membrane phospholipids, serve as ligands for immune cell receptors and many of their derivatives are potent immunoregulators.^{23,24}

Lipid mediators were classically linked to periodontal disease progression due to the production of proinflammatory mediators, such as prostaglandins and leukotrienes, through the arachidonic acid cyclooxygenase/lipoxygenase pathways. However, natural pro-resolving pathways of arachidonic acid metabolism have been discovered, such as lipoxins, resolvins and protectins, which are capable of modulating the host response to promote resolution of inflammation, in general, and in response to periodontopathogens, in particular.^{5,6,25}

Lipoxins are natural pro-resolving molecules derived from endogenous fatty acids. They stimulate the resolution of inflammation and promote the restoration of tissue homeostasis through a number of mechanisms, such as limiting the migration of polymorphonuclear neutrophils into sites of inflammation and modulating macrophage activity, inhibiting the secretion of proinflammatory cytokines.⁶ Lipoxin A₄ was described to block interleukin (IL) 1 beta (IL-1 β) and tumor necrosis factor alpha (TNF- α) release, consequently inhibiting leukocyte trafficking and attenuating inflammatory reactions elicited by *Porphyromonas gingivalis*, reinforcing its potential protective role in periodontal diseases.^{25–28}

Resolvins are products of dietary omega-3 polyunsaturated fatty acids (PUFAs) that also stimulate the resolution of inflammation through multiple mechanisms. Some studies have shown that resolvin E1 promotes resolution of inflammatory reaction, preventing the establishment of a chronic response after *P. gingivalis* infection, and also promoting the regeneration of periodontal connective tissue and bone.^{25,26} Newly discovered properties of resolvins show that these mediators may represent a new family of analgesics that are useful in treating inflammation-associated pain states such as arthritic and postoperative pain.²⁹

The benefits of dietary supplementation with omega-3 PUFAs have been proposed in many chronic inflammatory diseases, in animal models and clinical human

trials, such as type 2 diabetes, obesity, asthma, cancer, colitis and arthritis.^{29–32} It is also suggested that they may present anti-neuroinflammatory properties.³³

As fatty acids present high epithelial penetration ability, topical application has been successfully administered for treatment in experimental periodontitis in animal models.^{11,34,35}

Monounsaturated fatty acids (MUFAs) have comparable capacity with omega-3 PUFAs in suppressing proinflammatory cytokines and reducing expression of cell adhesion molecules in humans.³⁶

Evidence from epidemiological and controlled clinical studies have shown that MUFAs favorably affect a number of risk factors for coronary heart disease, including plasma lipids and lipoproteins, factors related to thrombogenesis, in vitro low-density lipoprotein oxidative susceptibility and insulin sensitivity in humans.³⁴

Recently, topical application of tetradecanol complex (TDC) was shown to restore the destructed periodontal tissues as a result of *P. gingivalis*-induced periodontal disease in a rabbit model of experimental periodontitis.^{34,35} The fatty acid complex was not only able to stop disease progression, but also resulted in new tissue and bone reformation, suggesting the potential novel therapeutic approach for the treatment of periodontal diseases.³⁵

The hypothesis of this study was that oral application of TDC to the gingiva of the cats with moderate-to-severe periodontal disease will reduce inflammation and improve oral health.

The aim of this study was to evaluate the outcome of the treatment of chronic periodontal disease with oral application of TDC in cats.

Materials and methods

The present study was performed at the Small Animal Clinical Sciences at the University of Saskatchewan, Canada. The study protocol was reviewed and approved by the Saskatchewan University Animal Research Ethics Board prior to study initiation. Thirteen cats were selected from the teaching and research colony of the Animal Resources Center. All animals were of a mixed breed. All cats were previously diagnosed with chronic periodontal disease and were on the waiting list for dental hygiene treatment at the Veterinary Teaching Hospital. These animals were included in previous studies at the university, but there was a washout period of 4 months. The patients received no drugs 4 weeks prior to the study.

All cats were kept free-housed and fed regular dry food (Cat Chow; Purina), canned food and tap water during the study period.

Study design

Full-mouth periodontal evaluations were performed under general anesthesia using intravenous propofol (4 mg/kg) and included probing pocket depth (PPD),

gingival index (GI), clinical attachment level (CAL), bleeding on probing (BOP), tooth mobility index (TMI) and furcation index, as described below. No tooth resorptions were found on oral clinical evaluation. No radiographs were performed in this study. No periodontal treatments such as dental scaling and polishing were performed. Teeth measured included maxillary and mandibular canines, upper third and fourth premolars, lower third and fourth premolars, and lower first molars.

The animals were randomly assigned to groups. The test group ($n = 9$) received 1-TDC (Elite Science; 525 mg per gel capsule/day), and the positive control group ($n = 4$) received olive oil (0.25 ml per gel capsule/day) as a placebo. Gel capsules were squeezed into their mouth, once daily, for 6 weeks. After 6 weeks of treatment, all cats were anesthetized for full-mouth periodontal evaluations. The study design is shown in Figure 1. All measurements were performed by a single examiner (JA), who was blinded to treatment allocations.

Periodontal measurements

All periodontal measurements performed were noted in the dental records for each patient at day 0 and after 6 weeks of treatment.

PPD PPD was assessed by measuring the depth of the gingival sulcus, from gingival margin to the coronal portion of the junctional epithelium, using a double-ended William's and Goldman Fox periodontal probe (GerMedUSA). Measurements were taken at six sites for each tooth: mesial, distal, buccal/labial at two sites and palatal/lingual at two sites. A recording of less than 1 mm was considered indicative of a healthy gingival sulcus.

GI The GI developed by Loe and Silness³⁷ was used: 0 (normal gingiva); 1 (mild inflammation, slight color change and edema, no bleeding); 2 (moderate inflammation, redness, edema, bleeding on probing); 3 (severe inflammation, marked redness and edema, ulceration, spontaneous bleeding).

CAL CAL was assessed by measuring the distance from the cementum–enamel junction to the coronal portion of the junctional epithelium, using a double-ended William's and Goldman Fox periodontal probe (GerMedUSA). Measurements were taken at six sites for each tooth.

BOP BOP was recorded for each tooth as present (1) or absent (0), 15 s upon probing.

TMI TMI, which classifies mobility from stages 0–3, was utilized. At stage 0, there is physiologic mobility up to 0.2 mm; at stage 1 mobility is increased in any direction other than axial over a distance of >0.2 mm and up to 0.5

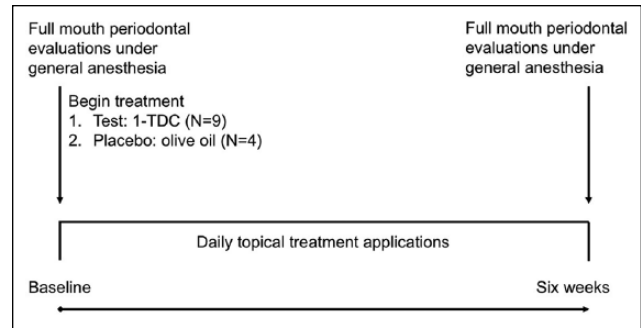


Figure 1 Study design. Thirteen cats were divided in two groups: 1-tetradecanol complex (1-TDC) and placebo (olive oil). Topical treatment initiated on baseline with duration of 6 weeks

mm; at stage 2 mobility is increased in any direction other than axial over a distance of >0.5 mm and up to 1.0 mm; and at stage 3 mobility is increased in any direction than axial over a distance exceeding 1.0 mm or any axial movement.

Furcation index The furcation index, which classifies the furcation involvement from stages 1–3, was used. At stage 1, furcation involvement exists when a periodontal probe extends less than half way under the crown in any direction of a multirrooted tooth with attachment loss; at stage 2, furcation involvement extends greater than half way but not through and through; and at stage 3, furcation exposure of a periodontal probe extends through and through from buccal to lingual or vice versa.

Statistical analysis

The unit of measurement was tooth present in the mouth. Each tooth was represented by a score obtained by the measurement of PPD, GI and CAL.

The mean \pm SDs were calculated for each cat and used for within-groups and between-groups comparisons before and after treatment.

Statistical analyses were performed using a paired *t*-test for within-group analysis and Student's *t*-test for group comparisons using SPSS (IBM). The level of significance was set at $P = 0.05$.

Results

Baseline parameters for both groups of cats (test and placebo) are represented in Table 1. No significant difference was found between groups at baseline with any parameters tested. All patients presented moderate-to-severe periodontal disease at baseline, with varying degrees of PPD, CAL, GI, BOP and mobility.

Clinical observations

No complications or adverse effects occurred during the study period. All cats continued their regular daily life

Table 1 Baseline parameters of periodontal evaluations of cats in both groups, with or without treatment with 1-tetradecanol complex (1-TDC)

Group	1-TDC group (test)	Olive oil (placebo)	P value
Cats (n)	9	4	
No. of teeth present	23.1 ± 8.1	25 ± 1.8	0.5
PPD (mm)	1.0 ± 1.0	1.3 ± 1.1	0.7
CAL (mm)	1.1 ± 0.9	1.7 ± 0.7	0.3
GI	2.4 ± 0.4	2.4 ± 0.9	1.0
BOP (%)	85.8 ± 15.9	89.8 ± 20.4	

Data are mean ± SD unless otherwise indicated

PPD = periodontal pocket depth; CAL = clinical attachment level;

GI = gingival index; BOP = bleeding on probing

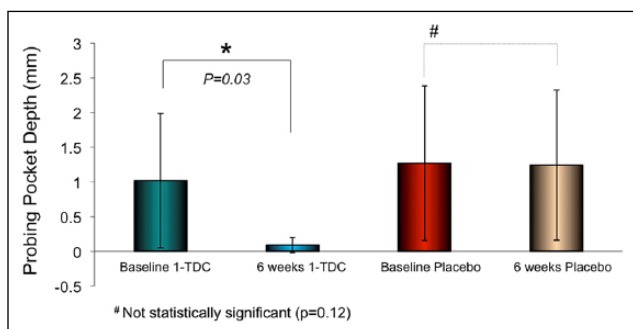


Figure 2 Impact of treatment with 1-tetradecanol complex (1-TDC) and placebo within and between groups according to probing pocket depth

with no obvious discomfort. Daily applications were easy, quick and had no negative impact on oral tissues or, in general, on the animals of the present study. No discomfort or behavioral changes were noted.

Cats were very cooperative and willing to get the daily applications, suggesting that the acceptance of topical 1-TDC and olive oil was high.

Periodontal evaluations

Data collected from PPD measurements were compared within the groups, from baseline to 6 weeks after treatment, and between the groups, treated with 1-TDC or olive oil (placebo), as shown in Figure 1. In the 1-TDC group, a statistically significant decrease in PPD was seen after 6 weeks of treatment, while no statistically significant difference was seen in the placebo group (Figure 2).

When evaluating CAL, the group receiving 1-TDC presented a mean ± SD measurement of 1.1 ± 0.9 mm at baseline, and of 0.7 mm after treatment ($P = 0.05$), while the placebo group experienced a slight, but not significant, increase in CAL ($P = 0.06$; Figure 3).

Statistically significant changes in GI were noted in the 1-TDC and placebo groups. A GI of 2.4 was seen at

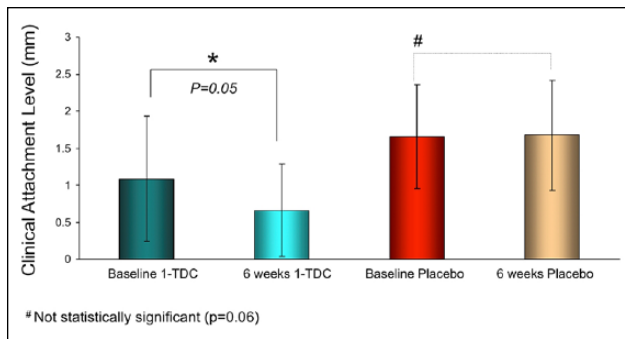


Figure 3 Impact of treatment with 1-tetradecanol complex (1-TDC) and placebo within and between groups according to clinical attachment level

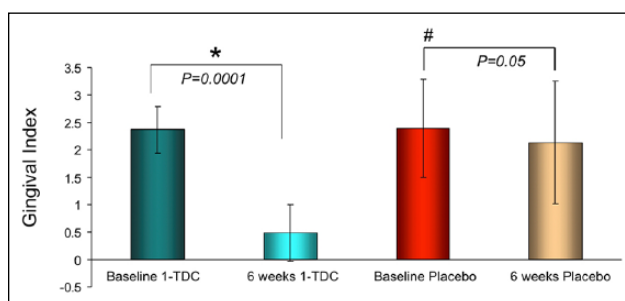


Figure 4 Impact of treatment with 1-tetradecanol complex (1-TDC) and placebo within and between groups according to gingival index

baseline for both the 1-TDC and placebo groups, but after 6 weeks of treatment, cats in the 1-TDC group had a reduced GI of 0.4 and those in the placebo group had a GI of 2 (Figure 4). Following these observations, similar findings in BOP were also seen within and between groups (Figure 5).

When evaluating tooth mobility, no difference was observed before and after application of placebo topicals. There was a decrease in tooth mobility in cats in the treatment group after treatment, but this was not statistically significant (Figure 6).

No statistically proven difference was found between the groups at baseline with regard to any of the parameters tested.

All patients presented with moderate-to-severe periodontal disease at baseline with varying degrees of PPD, CAL, GI, BOP and mobility.

Although the placebo group showed slightly more disease at baseline with respect to PPD, CAL and BOP, the difference was not statistically significant.

Cats in the 1-TDC group exhibited a statistically significant reduction in PPD, CAL, gingival index and BOP on probing after treatment at 6 weeks, whereas cats in the placebo group did not show any statistically significant change.

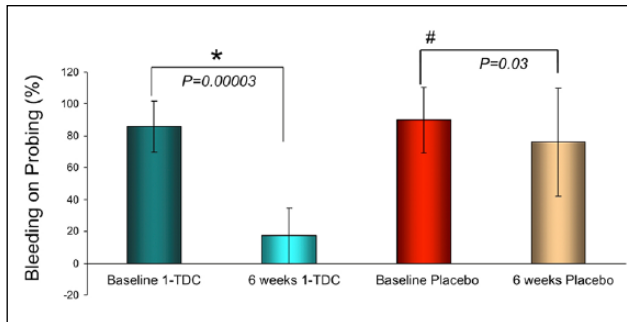


Figure 5 Impact of treatment with 1-tetradecanol complex (1-TDC) and placebo within and between groups according to bleeding on probing

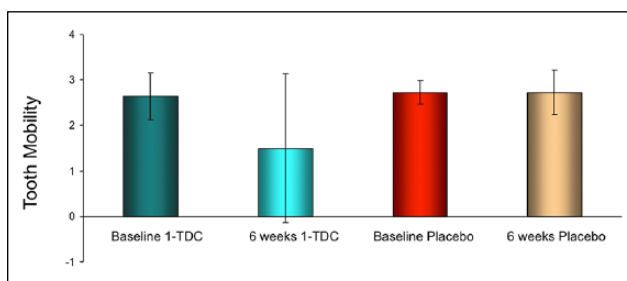


Figure 6 Impact of treatment with 1-tetradecanol complex (1-TDC) and placebo within and between groups according to tooth mobility index

Discussion

The pathophysiology of periodontal inflammation consists of two major pathogenic mechanisms. The first is direct toxicity of the microbiota present at the gingival sulcus, or periodontal pockets at the periodontal tissues. Enzymes and metabolites secreted by periodontopathogens cause dysfunction or death of periodontal tissues, such as the gingiva and periodontal ligament. The second, which has been considered the most damaging, is an indirect mechanism via a bacteria-modulated immune response. Pathogens trigger host cells to release inflammatory cytokines and other mediators, amplifying the immunological reaction. It results in destruction of host periodontal tissues, including alveolar bone as collateral damage.^{5,12}

Thus, autoimmune reactivity can play a regulatory role in tissue destruction and disease progression, although it may vary according to the type and stage of periodontal disease. The majority of responses seen in periodontitis are immunological.^{5,7,38} Periodontal diseases are characterized by dense accumulation of immune cells, including polymorphonuclear neutrophils, T and B lymphocytes, plasma cells, mast cells, monocytes and macrophages.^{39,40}

Bacterial components and products promote the chemotactic attraction of neutrophils and vasodilatation, as well

as the activation of host systems, such as the complement and kinin systems and the arachidonic acid pathways.⁷ This complex immunoinflammatory response results in severe destruction of the periodontium.^{7,10} Chronic inflammatory diseases, such as periodontal disease and rheumatoid arthritis, present dysregulated cytokine and immunoglobulin production at local disease sites, associated with infiltration of T lymphocytes, macrophages, neutrophils and plasma cells.^{13,38,41}

IL-1, IL-6 and TNF- α play central roles in the destruction of gingival tissues, including ligament fibers and alveolar bone in adult periodontitis. Most of these are secreted by T lymphocytes. Both IL-1 and TNF- α activate osteoclasts, which leads to bone resorption and inhibition of new bone synthesis.^{13,23}

Eicosanoids such as prostaglandins (PG) and leukotrienes are inflammatory mediators derived from cell membrane phospholipids by the action of cyclooxygenase or lipoxygenase on arachidonic acid. Lipoxygenase pathway catalyzes the formation of hydroxyeicosatetraenoic acids, leading to the formation of leukotrienes; and the cyclooxygenase pathway catalyzes the conversion of arachidonic acid into PGs, prostacyclins and thromboxanes. Inflamed gingiva synthesizes significantly larger amounts of PGs when incubated with arachidonic acid than does healthy gingiva. Many of these compounds have been implicated in the pathogenesis of periodontal diseases, that is, PGE₂ and leukotrienes (B₄, C₄, D₄, E₄), and are associated with alveolar bone resorption.^{6,42}

Management and control of dental plaque have been the main focus of prevention and treatment of periodontal diseases for many decades. At the beginning of the twenty-first century, modulation of the host response was included in the treatment protocol of periodontal disease.^{10,12}

Home care is essential for prevention and control of periodontal diseases. Many techniques and materials have been evaluated and developed to achieve the best possible results in the management of periodontal diseases. Mechanical, chemical and immunomodulatory agents can be used, and a combination of methods should be recommended.

They can act at different sites involved in periodontal disease progression, such as dental plaque, calculus, oral microbiota and inflammatory response, achieving better results for periodontal health.

Tooth brushing is still considered the gold-standard technique for mechanical removal of plaque and to control inflammation.^{43,44} Once the initiator of the cascade of periodontal disease is controlled, inflammation can be decreased. Dentifrices, oral rinses and gels, water additives, dental diets, treats, chew toys and dental barriers are examples of products used for oral health purposes.^{1,4,7,8,45}

The key to effective home treatment is compliance. Compliance is a significant issue in veterinary medicine. Although mechanical cleansing by frequent tooth brushing is an effective means of plaque control, compliance remains an issue. The simpler the required behavior, the more likely it is to be performed. If the complexity of the pet owner behavioral response is high, it is likely that the long-term effective compliance rate is going to be low.^{11,45} Efficient home care is often found to be very difficult and stressful as some cats simply do not cooperate.

The use of anti-inflammatory medications and/or systemic antibiotics has also been found to be useful in conjunction with mechanical treatment.^{7,46} Although it has been shown that long-term use of non-steroidal anti-inflammatory drugs (NSAIDs) reduces periodontitis in dogs, this strategy is not yet recommended as a clinically applicable approach to managing periodontal disease because the clinical effects of long-term use of NSAIDs have not yet been documented in dogs, and because of the presence of the well-known side effects of this type of medication.^{3,47} Likewise, the long-term use of antimicrobials in the management of periodontal disease cannot be encouraged owing to the unproven benefits and possible side effects.⁷

Alternative agents are being used as adjunctives to the surgical therapies for periodontitis, such as local antibiotic agents (doxycycline and clindamycin gels), or are being studied, such as fatty acids, bisphosphonates and IL-10.^{3,5,8}

Oral treatment with 1-TDC resulted in significant reductions in all parameters of clinical periodontal disease at 6 weeks, except tooth mobility. Compared with the placebo group, the 1-TDC group demonstrated significant reductions in CAL, GI and BOP on probing at 6 weeks. Mobility was dramatically reduced after treatment with topical 1-TDC; however, owing to the high variation between the groups of patients, the difference did not reach statistical significance.

As demonstrated in rabbits, 1-TDC stopped the progression of active periodontal inflammation and initiated restoration of the lost periodontium.^{34,35} However, evidence from the present study is limited to clinical changes, as no radiographic, histopathological or immunohistochemical analyses were performed.

Olive oil application on gingiva did not improve the periodontal health, yet no obvious disease progression was seen during the test period, suggesting a potential but weak anti-inflammatory effect of olive oil (oleic acid) on periodontal tissues, especially on gingiva, as slight reductions in GI and BOP were seen. Similar findings were observed in one study with experimental periodontitis in rabbits, and in a further study where olive oil was substituted by mineral oil.^{34,35}

Use of TDC results in significant improvements in gingival and periodontal health and can be an alternative,

safe and non-invasive therapeutic approach in cats suffering from destructive periodontal diseases.

Topical application of the oil was easily and quickly performed, and cats were receptive and willing to get the daily applications. The present study suggests that the tested presentation of 1-TDC could be easily included for a routine and effective home care, favoring the compliance of both the owner and the pet.

Combining strategies is likely to be more effective than relying on a single strategy, and modulation and control of inflammation have been demonstrated as essential parts of the treatment of chronic inflammatory diseases.

Significantly less periodontal tissue destruction occurs when the host's acquired immunity is absent or deficient when compared with that of the immunocompetent host. This classic periodontal treatment protocols were aimed at reducing the infective component and surgical correction of the damage occurring in hard and soft tissues. This novel approach, bringing more attention to the modification of host response and reducing the 'over-reactive' element, may bring hope of a cost-effective, non-surgical, successful periodontal therapy.^{3,10,12,23} The present study suggests that this modality of agent should be considered for managing periodontal diseases in cats and further studies in other species should be developed.

As stated by Harvey,³ prevention is a much more efficient option for the patient, and treating periodontitis does not make clinical sense if it is not accompanied by a prevention strategy that is likely to be followed long term.

Periodontal disease is not just a dental problem that causes bad breath and tooth loss, but is also an initiator of more severe systemic consequences.² It has been recently posited that periodontal therapy and metabolic control of diabetes in the early stages together can decrease both local and systemic oxidative stress in human diabetic patients.⁴⁸

Regeneration of soft and hard tissues lost to disease is a prominent problem in many inflammatory diseases, including periodontitis and arthritis.²⁸ The clinical results of the present study in cats, and also those observed in rabbit models,^{34,35} could be promising in this field, and further research should be performed.

The underlying mechanisms of action of 1-TDC is still not elucidated and more studies are recommended.

Conclusions


Chronic inflammation associated with periodontal diseases leads to periodontal tissue destruction. Modulation of the host response has been included in the treatment protocol for periodontal diseases. Fatty acids as anti-inflammatory agents are being investigated for use in the prevention and treatment of periodontal disease. The

present study suggests that this treatment modality should be considered in the management of periodontal diseases in cats. Studies with a longer follow-up and in other species should also be considered.

Acknowledgements The authors thank the University of Saskatchewan, Canada, especially Colette Wheeler, Colleen Zielke, Wanda Warren and Carla Hudy, for their help and assistance with this study.

Conflict of interest Presently James Anthony is an advisor for the manufacturer Elite Science, but at the time that the study was performed he had no involvement with the company.

Funding Olivier Morin of Waytouce LLC Consulting supplied the product for the study.

ORCID iD Fernanda Maria Lopes Kubitza  <https://orcid.org/0000-0003-3804-7579>

References

- Holmstrom SE. **Veterinary dentistry in senior canines and felines.** *Vet Clin North Am Small Anim Pract* 2012; 42: 793–808.
- Niemiec BA. **Periodontal Disease.** *Top Companion Anim Med* 2008; 23: 72–80.
- Harvey CE. **Management of periodontal disease: understanding the options.** *Vet Clin North Am Small Anim Pract* 2005; 35: 819–836.
- Bellows J. **Feline dentistry – oral assessment, treatment and preventive care.** Ames, IA: Blackwell Publishing, 2010.
- Tatakis DN and Kumar PS. **Etiology and pathogenesis of periodontal diseases.** *Dent Clin North Am* 2005; 49: 491–516.
- Cekici A, Kantarci A, Hasturk H, et al. **Inflammatory and immune pathways in the pathogenesis of periodontal disease.** *Periodontol* 2000 2014; 64: 57–80.
- Albuquerque C, Morinha F, Requicha J, et al. **Canine periodontitis: the dog as an important model for periodontal studies.** *Vet J* 2012; 191: 299–305.
- Niemiec BA. **Veterinary periodontology.** Ames, IA: John Wiley & Sons, 2013.
- Löe H, Theilade E and Jensen SB. **Experimental gingivitis in man.** *J Periodontol* 1965; 36: 177–187.
- Di Benedetto A, Gigante I, Colucci S, et al. **Periodontal disease: linking the primary inflammation to bone loss.** *Clin Dev Immunol* 2013; 2013: DOI: 10.1155/2013/503754.
- Logan EI. **Dietary influences on periodontal health in dogs and cats.** *Vet Clin North Am Small Anim Pract* 2006; 36: 1385–1401.
- Ńędzi-Góra M, Kowalski J and Górska R. **The immune response in periodontal tissues.** *Arch Immunol Ther Exp (Warsz)* 2017; 65: 421–429.
- Hamada S, Holt SC and McGhee JR. **Periodontal disease: pathogens and host immune responses.** Tokyo: Quintessence Publishing, 1991, p 410.
- DuPont GA and DeBowes LJ. **Comparison of periodontitis and root replacement in cat teeth with resorptive lesions.** *J Vet Dent* 2002; 19: 71–75.
- Reiter AM and Mendoza KA. **Feline odontoclastic resorptive lesions: an unsolved enigma in veterinary dentistry.** *Vet Clin North Am Small Anim Pract* 2002; 32: 791–837.
- Niemiec BA. **Oral pathology.** *Top Companion Anim Med* 2008; 23: 59–71.
- Dolieslager SMJ, Bennett D, Johnston N, et al. **Novel bacterial phylotypes associated with the healthy feline oral cavity and feline chronic gingivostomatitis.** *Res Vet Sci* 2013; 94: 542–544.
- Pavlica Z, Petelin M, Juntos P, et al. **Periodontal disease burden and pathological changes in organs of dogs.** *J Vet Dent* 2008; 25: 97–105.
- DeBowes LJ. **The effects of dental disease on systemic disease.** *Vet Clin North Am Small Anim Pract* 1998; 28: 1057–1062.
- DeBowes LJ, Mosier D, Logan E, et al. **Association of periodontal disease and histologic lesions in multiple organs from 45 dogs.** *J Vet Dent* 1996; 13: 57–60.
- Scannapieco FA. **Systemic effects of periodontal diseases.** *Dent Clin North Am* 2005; 49: 533–550.
- Lopez-Vicario C, Rius B, Alcaraz-Quiles J, et al. **Pro-resolving mediators produced from EPA and DHA: overview of the pathways involved and their mechanisms in metabolic syndrome and related liver diseases.** *Eur J Pharmacol* 2016; 785: 133–143.
- Schumann J. **It is all about fluidity: fatty acids and macrophage phagocytosis.** *Eur J Pharmacol* 2016; 785: 18–23.
- Rodrigues HG, Takeo Sato F, Curi R, et al. **Fatty acids as modulators of neutrophil recruitment, function and survival.** *Eur J Pharmacol* 2016; 785: 50–58.
- Garlet GP. **Destructive and protective roles of cytokines in periodontitis: a re-appraisal from host defense and tissue destruction viewpoints.** *J Dent Res* 2010; 89: 1349–1363.
- Serhan CN. **Pro-resolving lipid mediators are leads for resolution physiology.** *Nature* 2014; 510: 92–101
- Poorani R, Bhatt AN, Dwarakanath BS, et al. **COX-2, aspirin and metabolism of arachidonic, eicosapentaenoic and docosahexaenoic acids and their physiological and clinical significance.** *Eur J Pharmacol* 2016; 785: 116–132.
- Van Dyke TE. **Pro-resolving mediators in the regulation of periodontal disease.** *Mol Aspects Med* 2017; 58: 21–36.
- Souza PR and Norling LV. **Implications for eicosapentaenoic acid- and docosahexaenoic acid-derived resolvins as therapeutics for arthritis.** *Eur J Pharmacol* 2016; 785: 165–173.
- Viladomiu M, Hontecillas R and Bassaganya-Riera J. **Modulation of inflammation and immunity by dietary conjugated linoleic acid.** *Eur J Pharmacol* 2016; 785: 87–95.
- Vangaveti VN, Jansen H, Kennedy RL, et al. **Hydroxyoctadecadienoic acids: oxidised derivatives of linoleic acid and their role in inflammation associated with metabolic syndrome and cancer.** *Eur J Pharmacol* 2016; 785: 70–76.
- Schwanke RC, Marcon R, Bento AF, et al. **EPA- and DHA-derived resolvins' actions in inflammatory bowel disease.** *Eur J Pharmacol* 2016; 785: 156–164.
- Trépanier MO, Hopperton KE, Orr SK, et al. **N-3 polyunsaturated fatty acids in animal models with neuroinflammation: an update.** *Eur J Pharmacol* 2016; 785: 187–206.
- Hasturk H, Jones VL, Andry C, et al. **1-Tetradecanol complex reduces progression of porphyromonas gingivalis-induced experimental periodontitis in rabbits.** *J Periodontol* 2007; 78: 924–932.

- 35 Hasturk H, Goguet-surmenian E, Blackwood A, et al. **1-Tetradecanol complex: therapeutic actions in experimental periodontitis.** *J Periodontol* 2009; 80: 1103–1113.
- 36 De Caterina R, Liao JK and Libby P. **Fatty acid modulation of endothelial activation.** *Am J Clin Nutr* 2000; 71 1 Suppl: 213S–223S.
- 37 Loe H and Silness J. **Periodontal disease in pregnancy.** *Acta Odontol Scand* 1963; 21: 533–551.
- 38 Ali J, Pramod K, Tahir MA, et al. **Autoimmune responses in periodontal diseases.** *Autoimmun Rev* 2011; 10: 426–431.
- 39 Arzi B, Murphy B, Cox DP, et al. **Presence and quantification of mast cells in the gingiva of cats with tooth resorption, periodontitis and chronic stomatitis.** *Arch Oral Biol* 2010; 55: 148–154.
- 40 Silva N, Abusleme L, Bravo D, et al. **Host response mechanisms in periodontal diseases.** *J Appl Oral Sci* 2015; 23: 329–355.
- 41 Binderman I, Gadban N and Yaffe A. **Extracellular ATP is a key modulator of alveolar bone loss in periodontitis.** *Arch Oral Biol* 2017; 81: 131–135.
- 42 Sengupta S, Fine J, Wu-Wang CY, et al. **The relationship of prostaglandins to cAMP, IgG, IgM and α -2-macroglobulin in gingival crevicular fluid in chronic adult periodontitis.** *Arch Oral Biol* 1990; 35: 593–596.
- 43 Watanabe K, Hayashi K, Kijima S, et al. **Tooth brushing inhibits oral bacteria in dogs.** *J Vet Med Sci* 2015; 77: 1323–1325.
- 44 Harvey C, Serfilippi L and Barnvos D. **Effect of frequency of brushing teeth on plaque and calculus accumulation, and gingivitis in dogs.** *J Vet Dent* 2015; 32: 16–21.
- 45 Niemiec BA. **Periodontal therapy.** *Top Companion Anim Med* 2008; 23: 81–90.
- 46 Kim SE, Kim S, Jeong M, et al. **Experimental determination of a subantimicrobial dosage of doxycycline hyclate for treatment of periodontitis in Beagles.** *Am J Vet Res* 2013; 74: 130–135.
- 47 Monteiro-Steagall BP, Steagall PVM and Lascelles BDX. **Systematic review of nonsteroidal anti-inflammatory drug-induced adverse effects in dogs.** *J Vet Intern Med* 2013; 27: 1011–1019.
- 48 Aral CA, Nalbantoğlu Ö, Nur BG, et al. **Metabolic control and periodontal treatment decreases elevated oxidative stress in the early phases of type 1 diabetes onset.** *Arch Oral Biol* 2017; 82: 115–120.